

An Unusual Infective Mimic of ulcerative Colitis

Authors-Vaishali Ranade,Fiona Murdoch,Indranil Banerjee,Hasnain Jafferbhoy,Sian Gilchrist ,Victoria Hospital,NHS Fife



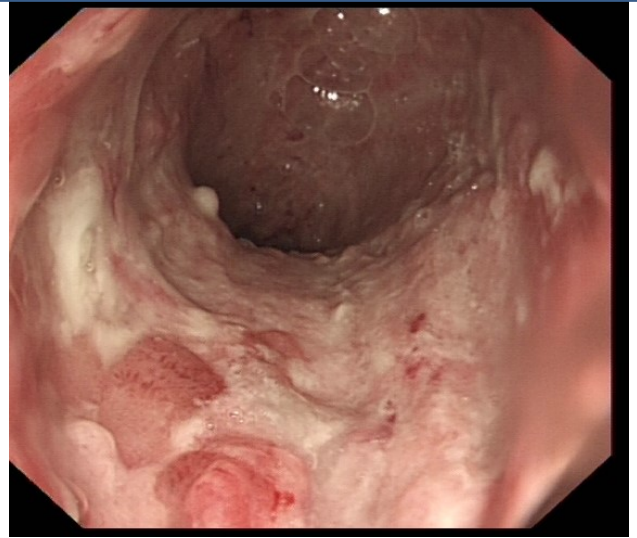
Introduction

There are several diseases that mimic Inflammatory Bowel Disease (IBD). Many infections present with clinical, histopathological and endoscopic findings similar to IBD. A high index of suspicion is required in patients poorly responding to appropriate therapies. We would like to present an apparent case of ulcerative colitis.

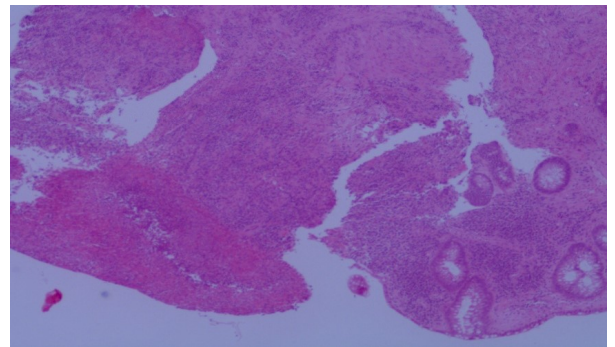
Case History

We present a case of a young adult male patient with bloody diarrhoea, who underwent investigations revealing ulcerative colitis on flexible sigmoidoscopy and biopsy in 2017. His sexual history and colonoscopy appearances initiated STI infection screen. However, he declined rectal swab examination. He was treated with steroids and immunosuppression with moderate success. The clinical course was complicated by CMV colitis which was treated appropriately with valganciclovir.

Despite this treatment, his colitis remained active. His disease was reassessed with repeat sigmoidoscopy and biopsy. Once again the possibility of STI was raised. Rectal swab confirmed Lymphogranuloma venereum (LGV) infection. Retrospectively the biopsies were screened for LGV PCR, which returned positive. His immunosuppression was stopped, and he commenced on antibiotics. A follow-up sigmoidoscopy has been arranged.



Deep ulcers in the rectum



Histopathology shows abrupt ulcerations with lack of chronicity.

Conclusion-It is important to consider Sexually transmitted infections as differential for Colitis. LGV is a well-recognized cause of proctitis which occasionally presents to Gastroenterology, often seen in patients with HIV. Close collaboration of Gastroenterology and Genitourinary teams is needed to manage such cases.